

Clinical Case Review

Assessment of Right MCA Clot Using Vitrea® Software

Jeffrey S. Carpenter, MD

Section Chief, Neuroradiology and Interventional Neuroradiology
Associate Professor of Radiology, Neurology and Neurosurgery
West Virginia University Hospital, Morgantown, WV

INTRODUCTION

The patient is a 62-year-old female who was brought to the West Virginia University (WVU) Hospital Emergency Department (ED) with fluctuating left-sided weakness approximately three hours after symptom onset. One day prior, she had undergone placement of a drain for an abdominal abscess. While she was not a candidate for intravenous tissue plasminogen activator (TPA), she was a possible candidate for intra-arterial techniques.

METHOD

The patient underwent the Computed Tomography (CT) stroke protocol to evaluate for hemorrhage.

FINDINGS

The non-contrast head CT volumes were loaded into the Vitrea® system to evaluate for hemorrhage. A slight volume loss visible as increased prominence in the cerebellar folia (see Figure 1) was observed, with no other remarkable findings in the cerebellum.

A small region of decreased attenuation next to the left caudate in the anterior limited internal capsule (see Figure 2) was visualized. Although indeterminate, it could be either a remote or recent infarct.

Narrowing the Window Width down and the Window Level up the contrast was satisfactory, and a difference between gray and white matter appreciated. While the left putamen, left caudate head and right caudate head were visible, the right putamen and globus pallidus were missing from view (see Figure 3), indicating an early stroke. No hemorrhage was observed. Information conflicted at this point, having identified a small lacunar infarct of indeterminate age in the left region and more acute findings of decreased attenuation in the right basil ganglia.

Next, the Brain Perfusion CT protocol was used to evaluate the lower levels of perfusion imaging. The data set was acceptable with very little motion. The image revealed a complete Circle of Willis (see Figure 4).

Figure 1: CT Visualization of Cerebellum

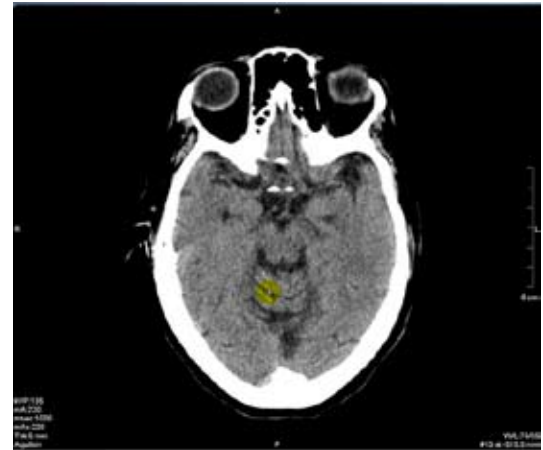


Figure 2: Region of Decreased Attenuation

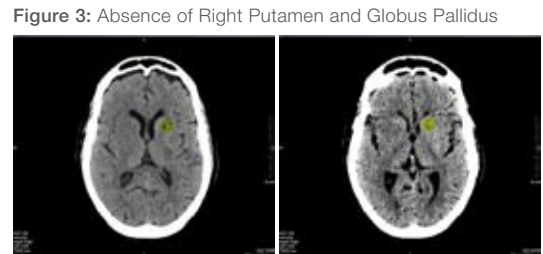


Figure 3: Absence of Right Putamen and Globus Pallidus

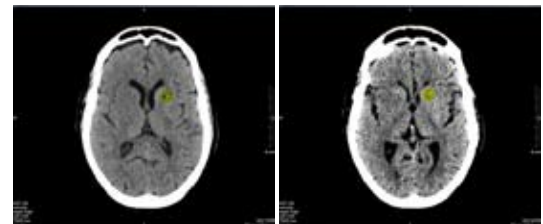
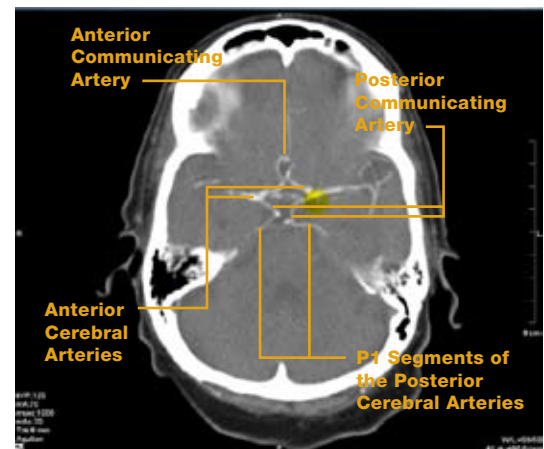


Figure 4: Visualization of Complete Circle of Willis



Clinical Case Review

Assessment of Right MCA Clot Using Vitrea Software

Motion Correction was utilized to compute perfusion analysis. After adjusting the axis and scrolling up through the images, the mean transit time abnormality was noted in the right MCA territory (see Figure 5), decreased cerebral blood flow, and some areas of decreased cerebral blood volume (CBV) in the basal ganglia region and the anterior division of the right MCA, indicating a significant level of infarct at this level. Cerebral blood flow abnormality extended throughout the right MCA territory, along with relatively isolated CBV abnormalities. There was a relatively substantial area of residual penumbra, mainly in the posterior division of the right MCA and some tissue already infarcted in the anterior division.

The second level of perfusion study volumes were loaded using the Brain Perfusion CT protocol to evaluate the degree and persistence of salvageable brain. The auto-segmented vessels were accepted and the system computed perfusion analysis. A relatively large right MCA stroke (see Figure 6) was visualized. However, a portion of the R MCA territory had preserved blood volume, indicating a large number of penumbra were maintained in this area.

The stroke clock was at three hours, and intra-arterial techniques were chosen as the attempted intervention. The CT angiogram (CTA) was used to detail the right MCA region. Using thick MIPS, the right MCA occlusion (see Figure 7) was visualized.

Thin slab axials were used to examine bifurcation in the aortic arch and survey potential blood clot origination sites. Several arteries and a “bovine configuration” (a normal variant in which the left common artery comes off of the brachiocephalic artery) (see Figure 8) were identified. Stenosis or ulcerations in the right carotid bifurcation region or anything that suggested a dissection were not observed.

Figure 5: Visualization of Mean Transit Time Abnormality

Figure 6: Identification of Right MCA Stroke

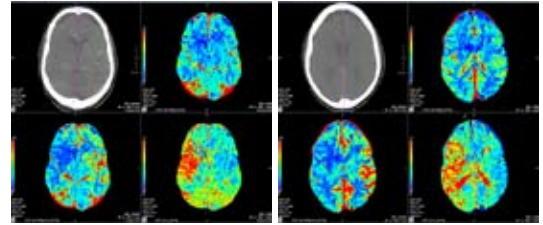


Figure 7: Thick MIPS Rendering of Right MCA Occlusion

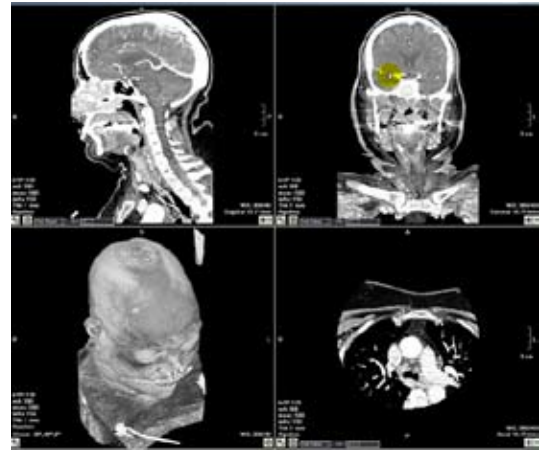
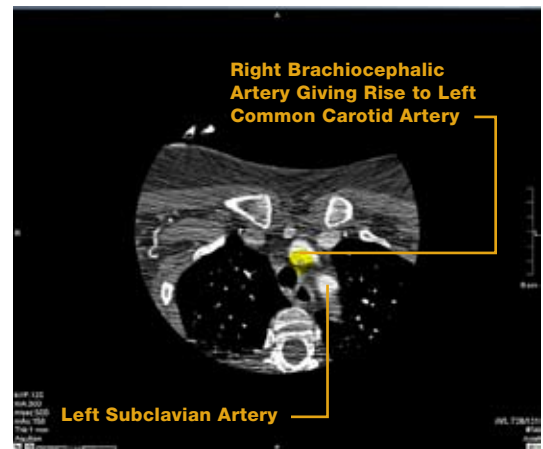


Figure 8: Thin Slab Axial Views of Vessels



Clinical Case Review

Assessment of Right MCA Clot Using Vitrea Software

At the right MCA, an abrupt occlusion and clot in the main segment were observed. They became more visible when the slices were thickened (see *Figure 9*). Some Sylvian branches were visible, however, indicating some flow.

With the patient's level of salvageable brain, it was determined worthwhile to attempt to remove the clot. The patient was moved to the Angio Suite, where she underwent intervention. The initial angiogram (see *Figure 10*) revealed the occluded right MCA, as well as good collateral flow from the anterior cerebrals filling backwards into the MCAs. A posterior cerebral artery arising from the superclinoid was noted, a very large posterior communicating artery supplying the majority of flow to the PCA, and the anterior cerebral artery. However, the MCA branches over the insula were missing from view.

Moving out a little further, filling of the arteries in retrograde fashion was observed. There was very good collateral blood flow in the posterior segment, but not in the anterior (see *Figure 11*).

The angiogram was performed through a microcatheter seated next to the clot, which was used to infuse ~8 mg TPA (see *Figure 12*).

Figure 9: Observation of Occlusion and Clot

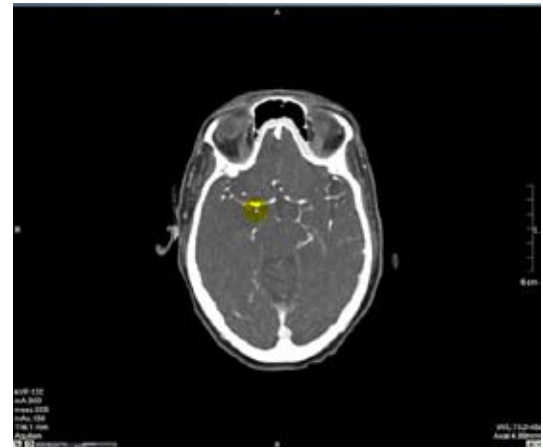


Figure 10: Pre-Intervention Angiographic View of Collateral Flow

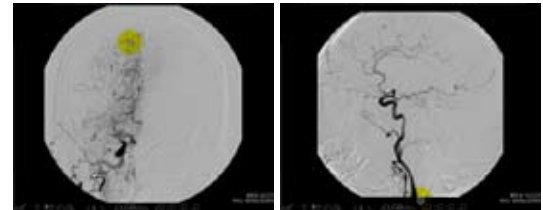
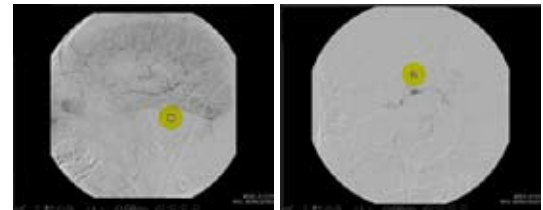


Figure 11: Retrograde Filling of the Posterior Segment

Figure 12: Seating of Microcatheter Next to Clot



Clinical Case Review

Assessment of Right MCA Clot Using Vitrea Software

Ideally this would have been a good case for mechanical retrieval with the Penumbra MERCI™ device, but proximal access issues prohibited doing so. In a minority of such cases, tortuosity in the neck or skull base prohibits access to the intended vessel. Additionally, not all clots respond to intra-arterial thrombolytics. In this case, flow was not restored (see *Figure 13*).

Finally, the DWI sequence was loaded using the Head MR protocol. After selecting a 2D image, the right MCA stroke (see *Figure 14*) was visualized. A large infarct was noted at the time of presentation in the anterior segment of the brain reflected in the diffusion-weighted sequence involving all of the insula confluenty. Moving further back into the posterior division, involvement was very patchy. This anterior predominance and patchy appearance indicated that collateral flow was somewhat compensated. However, the intervention in this case probably did not make any real difference in what turned out to still be a very big infarct.

CONCLUSION

Upon arrival at the WVU Hospital ED, the patient underwent CT stroke protocol, which revealed right MCA clot. Though the clot was visualized and accessed with smaller microcatheters, the stroke could not ultimately be addressed with mechanical retrieval. The patient remained relatively stable with regard to her neurologic symptoms with a dense left hemiparesis involving upper and lower extremities as well as a left facial droop, right gaze preference and extinction to the left side. The patient had dysarthria secondary to her left-sided weakness but no aphasia that is typically a left hemisphere finding.

Figure 13: Follow-up Angiogram Depicting Failure to Restore Flow

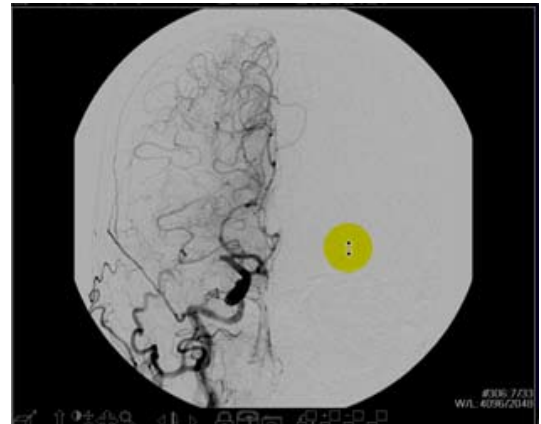

Figure 14: Confluent Involvement in the Anterior Segment

