

Clinical Case Review

Assessment of Bypass Graft Patency and Mechanical Valve Function in a Patient with Unusual Anatomy Using Vitrea® Software

Wojciech Mazur, MD, FACC

Director, Cardiac CT Training

Director, Advanced Cardiac Imaging

Associate Professor of Clinical Medicine and Pediatrics

The Christ Hospital, Cincinnati, OH

wmazur@cardiac-cta.com

www.ohioheartandvascular.com

www.christhospitalcincinnati.com

INTRODUCTION

This is an unusual case of a young, 29 year old intravenous drug user, who initially presented with cardiogenic shock and aortic root abscess. He underwent emergent aortic valve replacement and was discharged home 10 days later in stable condition. Three months after his surgery, he underwent tooth extraction and prophylactic antibiotics were not administered. Shortly after he presented with congestive heart failure.

Transesophageal echocardiogram revealed large recurrent aortic root abscess and infected mitral valve. Patient underwent emergent surgery; intraoperatively he was found to have a massive abscess cavity measuring 6 x 7 cm and multiple vegetation and perforation of anterior leaflet of the mitral valve. Due to the large cavity occupying the left ventricular outflow tract, aortic prosthesis had to be implanted high in the ascending thoracic aorta. His LM and proximal RCA were ligated and bypassed using venous grafts (native coronary ostia are now located below the prosthetic aortic valve). Mitral valve was replaced with mechanical St. Jude prosthesis. Patient recovered from his surgery and three years later presented for assessment of chest pain and dyspnea.

METHOD

The patient was initially imaged in April 2007 using CT.

FINDINGS

Using the Cardiac Arteries protocol, the Vitrea® software generated a 3D color image. The evaluation began by making a quality assessment of the original CT images while segmentation was in process. Contrast intensity exceeded 250 throughout the entire ventricle (see Figure 1).

Misregistration artifact most often affects the mid-RCA. However, evaluation revealed that the only artifact present in this patient's imaging was beam hardening artifact from sternal wires (see Figure 2).

A bypass graft attached to the LAD (see Figure 3) was visualized and properly tracked through the native vessel in the left coronary system. Ligation of the left main artery was observed and confirmed using the orthogonal view (see Figure 4).

Figure 1: Quality Assessment Using Contrast Intensity

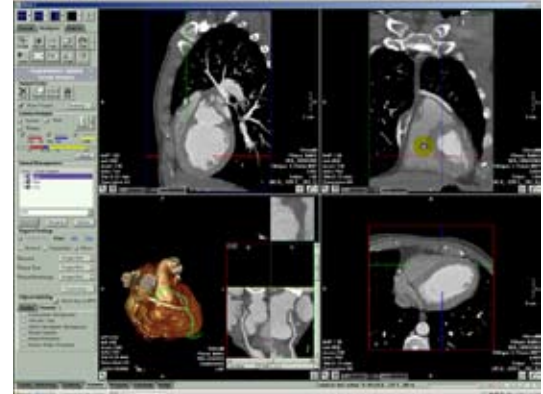

Figure 2: Evaluation of Misregistration Artifact

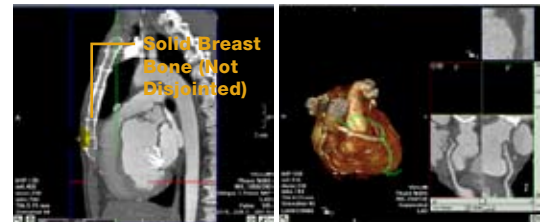
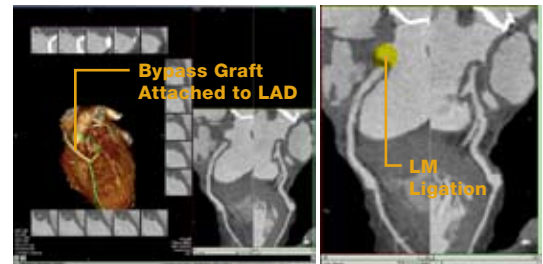


Figure 3: Analysis of Coronary System



Clinical Case Review

Assessment of Bypass Graft Patency and Mechanical Valve Function in a Patient with Unusual Anatomy Using Vitrea Software

Continuing in this view, it was noted the aortic valve was replanted high in the ascending aorta (see Figure 5).

There is a severe LM stenosis in absence of a plaque, caused by intentional surgical ligation (see Figure 8).

The vessel was manually selected and probed to track the graft down to the left coronary system with ease (see Figure 6).

The system rendered a perfect layout of the graft, from which anastomosis in the first vessel (see Figure 7) was identified.

Figure 4: Orthogonal View for Assessment of Ostial Coronary Anatomy

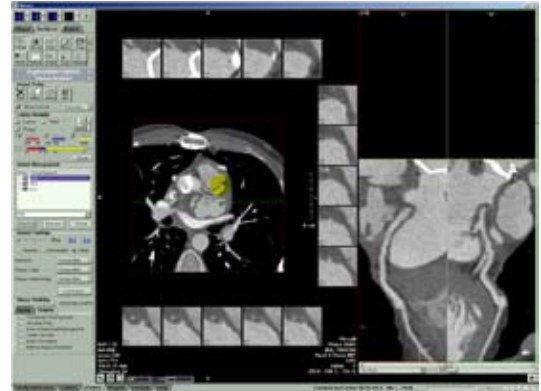

Figure 5: *Top image:* Large residual abscess cavity in anatomical location of the aortic valve.
Bottom image: Prosthetic aortic valve in ascending thoracic aorta.

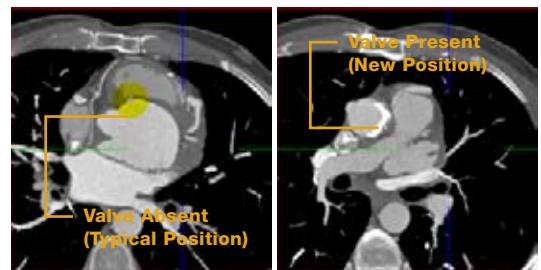
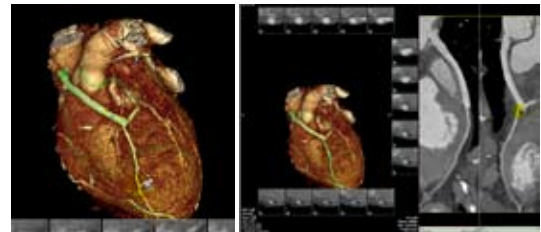


Figure 6: Manual Selection and Probe of the Graft

Figure 7: Confirmation of Graft



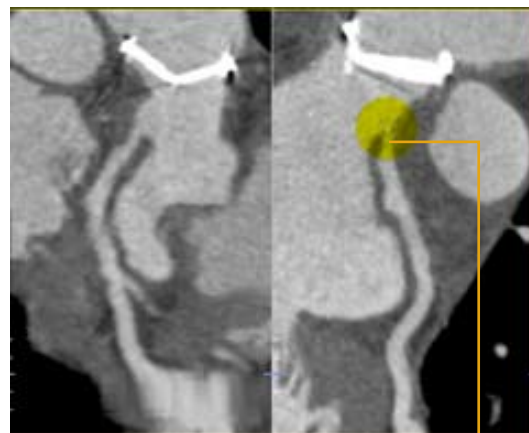
Clinical Case Review

Assessment of Bypass Graft Patency and Mechanical Valve Function in a Patient with Unusual Anatomy Using Vitrea Software

The left main vessel was then selected and tracked to visualize the left coronary system (see *Figure 8*).

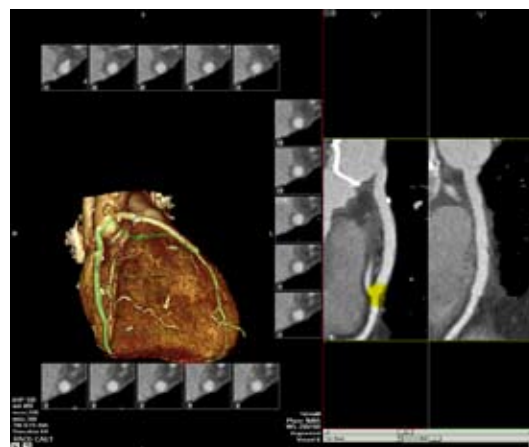
Next, the graft to the right coronary system was tracked. The system performed rapid analysis, allowing the anastomosis site to be immediately identified without an extensive search (see *Figure 9*).

Figure 8: Visualization of Left Coronary System



There is a severe LM stenosis in absence of a plaque, caused by intentional surgical ligation

Figure 9: Visualization of Right Coronary System



Clinical Case Review

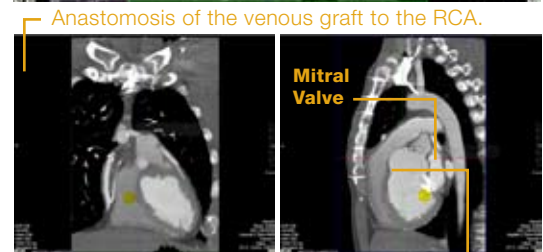
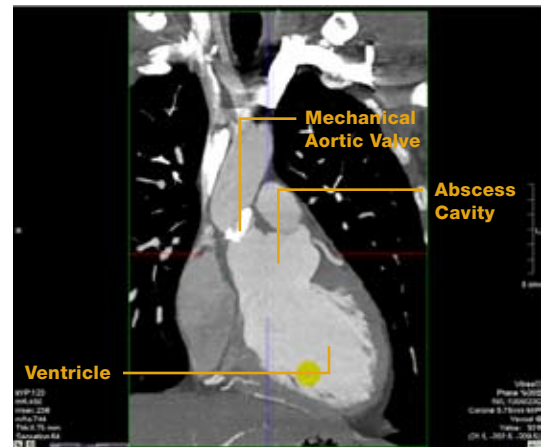
Assessment of Bypass Graft Patency and Mechanical Valve Function in a Patient with Unusual Anatomy Using Vitrea Software

Finally, the Vessel Probe function was turned off to review cardiac morphology (see Figure 10 and Figure 11). High placement of the aortic valve was noted, as well as the extensive size of the old abscess cavity.

CONCLUSION

This complex case was reviewed in under 10 minutes and confirmed graft patency and normal function of prosthetic mitral and aortic valve. In this case due to high position in the ascending aorta, mechanical aortic valve could not be visualized with echocardiography.

Figure 10: Review of Cardiac Morphology



Residual abscess cavity compressing right ventricular outflow tract in systole

Figure 11: Continuation of Cardiac Morphology Review

