

Clinical Case Review

Assessment of Multi-Vessel Coronary Artery Disease Using Vitrea® Software

Michael Steigner, MD

Attending Radiologist

Non-Invasive Cardiovascular Imaging

Brigham and Women's Hospital, Boston, MA

msteigner@partners.org

INTRODUCTION

The patient is a 72-year-old man.

Dr. Michael Steigner imaged and evaluated the patient.

METHOD

Brigham and Women's Hospital initially imaged the patient using CT.

FINDINGS

Using the Cardiac Arteries protocol, the Vitrea® software generated a 3D color image. The evaluation began by removing unwanted tissue from the image using the Window and Level tools. The automated segmentation of vessels was analyzed and manually tracked and several vessel segments were relabeled. A collateral vessel connecting the right coronary artery (RCA) to the circumflex (CX) (see Figure 1) was observed.

The left atrial appendage (LAA) was cropped out, which was obstructing the view of the vascular anatomy (see Figure 2).

Figure 1: Visualization of Collateral Vessel

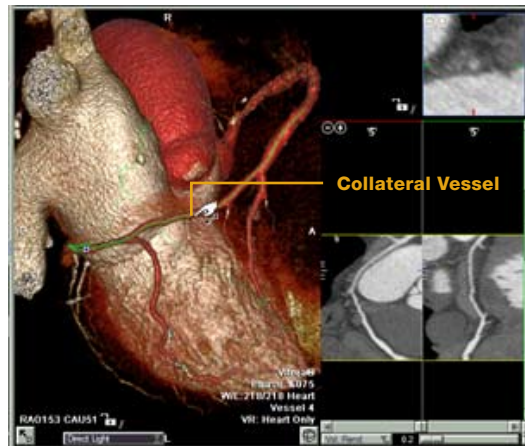
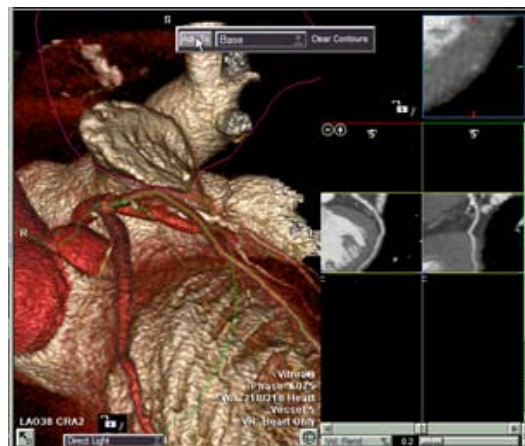


Figure 2: Selection of LAA for Removal from Image



Clinical Case Review

Assessment of Multi-Vessel Coronary Artery Disease Using Vitrea Software

Once the LAA was added to the base, a Ramus branch was visualized on the anatomy, the first obtuse marginal (OM_1), the second obtuse marginal (OM_2), the acute marginal branch (AM) and a septal branch (see *Figure 3*).

Once all the desired vessels were labeled, the case was reviewed beginning with evaluation of the left main artery (LM) (see *Figure 4*). Mixed plaque (i.e., calcified and non-calcified) was found in the LM and an associated stenosis of 50–70% (per the institution's gestalt method of grading).

The proximal left anterior descending artery (LAD) contained soft plaque with narrowing of the lumen and a 50–70% lesion (see *Figure 5*).

Figure 3: Visualization of Vascular Anatomy

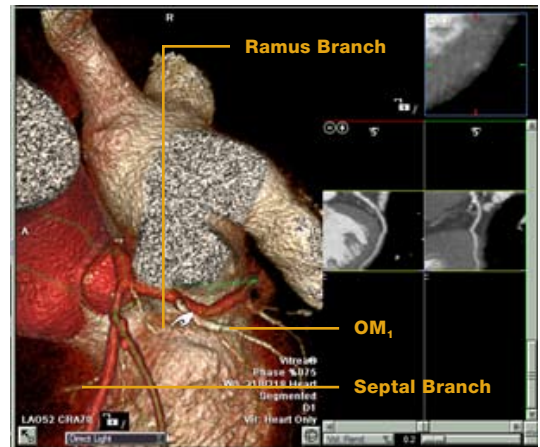


Figure 4: Evaluation of LM

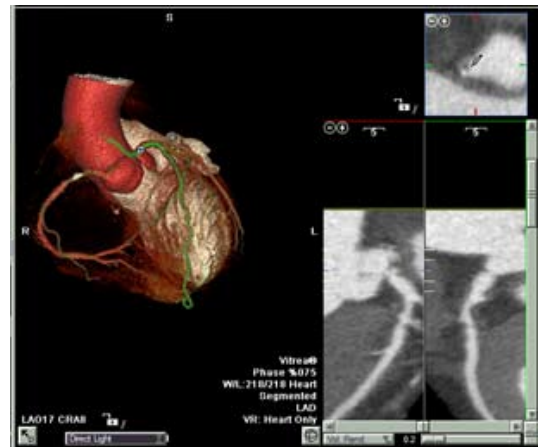
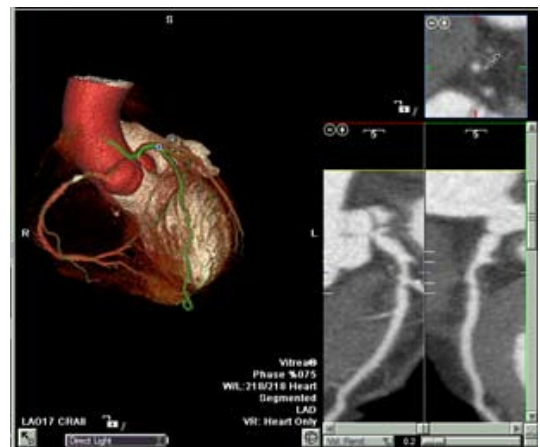

Figure 5: Evaluation of the Proximal LAD



Clinical Case Review

Assessment of Multi-Vessel Coronary Artery Disease Using Vitrea Software

A myocardial bridge in the mid-LAD with a small amount of myocardium over the vessel (see Figure 6) was observed.

The ostium of the first diagonal branch (D₁) also contained complex plaque with a 50–70% lesion (see Figure 7).

Plaque in the left circumflex (LCX) was visualized with no significant stenosis (see Figure 8) and a large collateral vessel joining the LCX and RCA (see Figure 9).

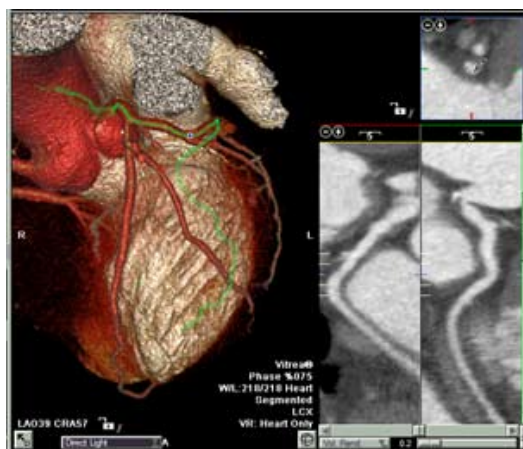
Figure 6: Evaluation of the Mid-LAD

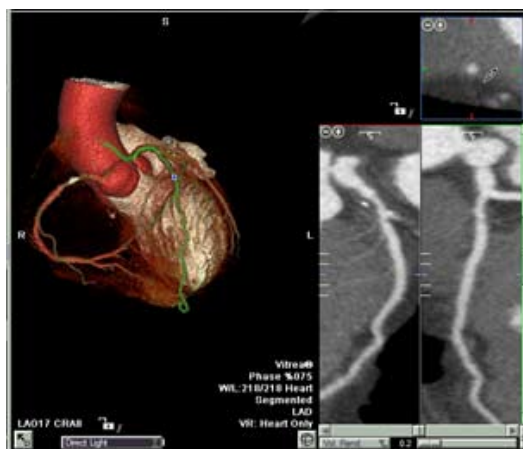

Figure 7: Evaluation of D₁

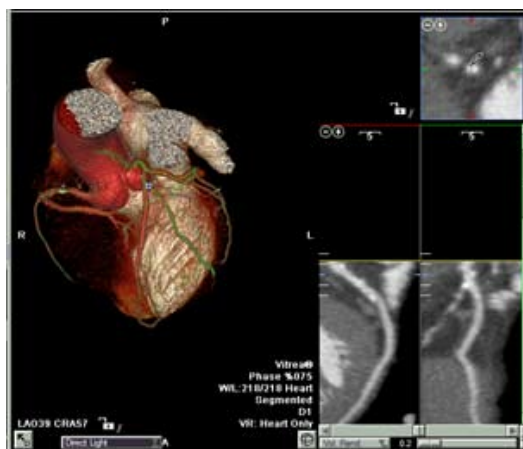

Figure 8: Evaluation of LCX



Clinical Case Review

Assessment of Multi-Vessel Coronary Artery Disease Using Vitrea Software

The origin of OM₁ contained complex plaque with a related stenosis of at least 50–70% (possibly greater) (see Figure 10). OM₂ contained complex plaque, as well (see Figure 11).

Returning to the RCA, the proximal segment contained heavily calcified plaque with a complete occlusion was noted, which explained the large collateral vessel coming from the other side of the heart (see Figure 12). The remainder of the RCA contained complex plaque running the entire course of the vessel with another 50–70% lesion in the mid-RCA.

CONCLUSION

Significant multi-vessel disease was identified in this patient, including total occlusion of the RCA with collateralization from the LCX and multiple other significant stenoses. Based on these findings, a cath procedure was recommended for this patient. The Vitrea system was used to create snapshots of each vessel, including the C-arm orientations, to assist in the interventional procedure.

Figure 9: Identification of Collateral Vessel

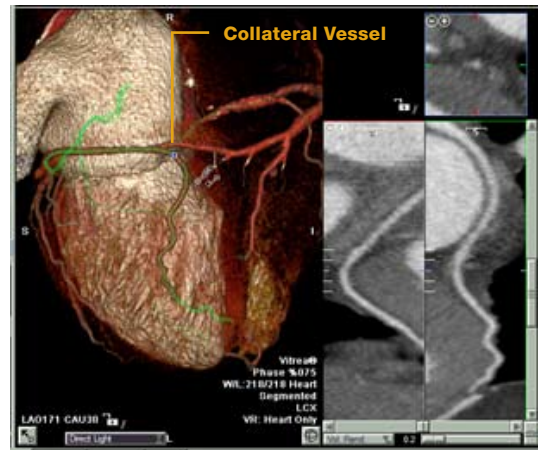


Figure 10: Evaluation of OM₁ Figure 11: Evaluation of OM₂

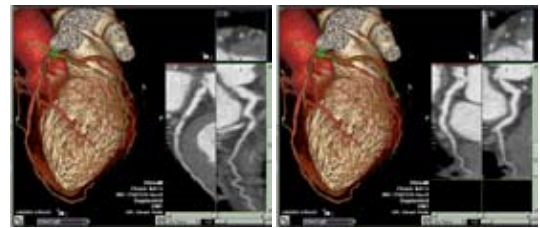


Figure 12: Evaluation of RCA

