

# Clinical Case Review

## Evaluation of Questionable Ischemic Apex Using Vitrea® Software

### Michael Steigner, MD

Attending Radiologist

Non-Invasive Cardiovascular Imaging

Brigham and Women's Hospital, Boston, MA

msteigner@partners.org

### INTRODUCTION

The patient is a 42-year-old man who had a myocardial perfusion that showed questionable ischemia of the apex. He did not want a cath and opted for a coronary Computed Tomography (CT) study.

Dr. Michael Steigner imaged and evaluated the patient in this case.

### METHOD

Brigham and Women's Hospital initially imaged the in January 2008 using CT.

### FINDINGS

Using the Cardiac Arteries protocol, the Vitrea software generated a 3D color image. The case began by evaluating the volume. A vessel coursing anterior to the pulmonary outflow tract (see Figure 1) was noted.

Using the 2D axial view, the left main (LM) artery was viewed. There was no vessel originating from the left coronary cusp (see Figure 2).

The images were scrolled to right coronary cusp to visualize a single right coronary artery (RCA) (see Figure 3). The RCA gave rise to a large vessel coursing anterior and following the distribution of the LAD and another vessel coursing posterior to the sinus of Valsalva in between the atrium and the aortic root. The latter vessel gave rise to another vessel taking the path of the diagonal branch (D<sub>1</sub>) and the circumflex (CX).

Figure 1: Visualization of Vasculature

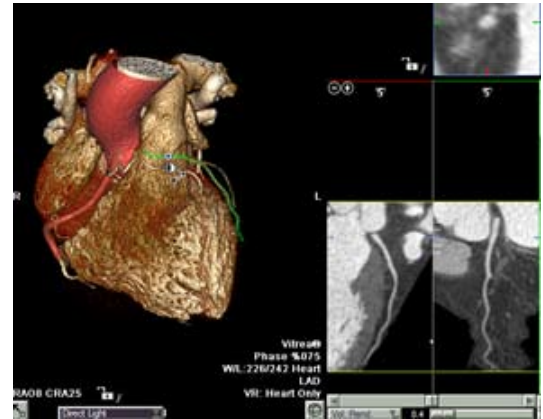


Figure 2: Axial View of LM Absence

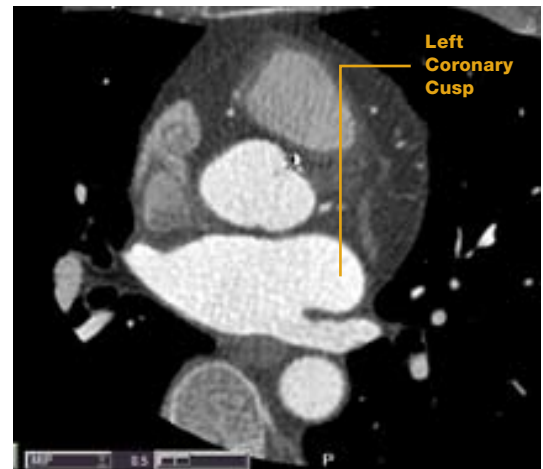
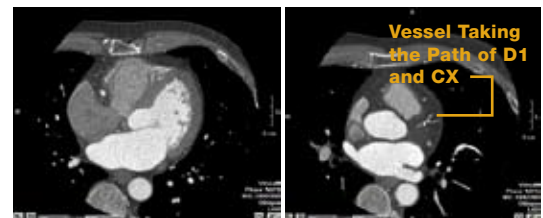


Figure 3: Visualization of Right Coronary System



# Clinical Case Review

## Evaluation of Questionable Ischemic Apex Using Vitrea Software

To better advantage the 3D view, the automatically picked LAD and CX from Vessel Management was deleted and the left atrium using the Multi-Object Segmentation Tool (see Figure 4) was removed.

The Window Level tool enabled removal of extra tissue, providing a clear view of the vascular anomaly between the left ventricular outflow tract and the left atrium (see Figure 5).

The opacity of the heart tissue was further adjusted to review the segmented vessels, beginning with the LAD (see Figure 6). The ostium of the LAD looked normal. Additionally, the vessel itself was unremarkable with no significant stenosis.

Figure 4: Selection of LA for Removal from 3D View

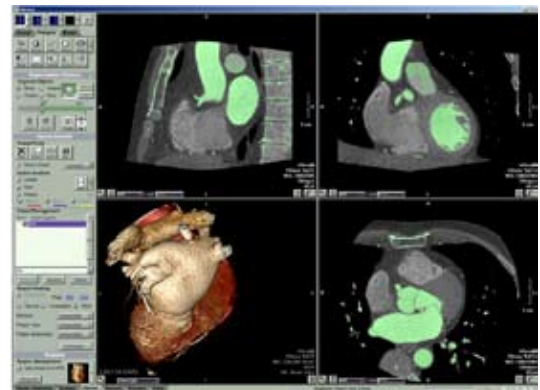

Figure 5: 3D View of Anomalous Vessel

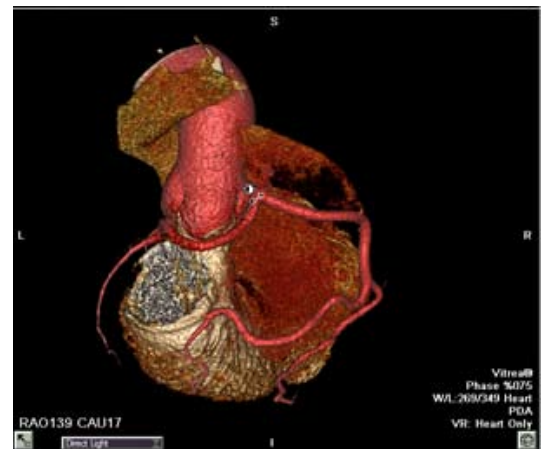
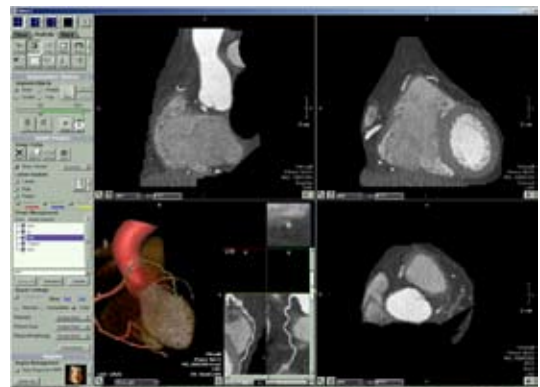


Figure 6: Evaluation of the LAD



# Clinical Case Review

## Evaluation of Questionable Ischemic Apex Using Vitrea Software

The D<sub>1</sub> rising from the RCA was evaluated and it appeared normal (see Figure 7).

The left circumflex (LCX) was a very small vessel. It shared a common trunk with D<sub>1</sub> and appeared to be normal. The Double Oblique MPR Mode allowed a better view of the ostium. However, while the LCX was too small to interpret, it appeared patent (see Figure 8).

Finally, the two large branches of the RCA — a large PLV branch and a PDA branch were evaluated. Both vessels appeared normal (see Figure 9). No plaque was observed in this patient.

### CONCLUSION

A solitary coronary artery with a non-malignant course in which no vessels traversed between the aorta and the pulmonary artery was identified. The vessels were not at risk of ischemia. Coronary artery disease was not evident. The finding on the nuclear study was likely secondary to diaphragmatic artifact. The case was concluded in less than 10 minutes. If desired, a batch movie to send to PACS to assist clinicians with visualization could be generated.

Figure 7: Evaluation of D<sub>1</sub>

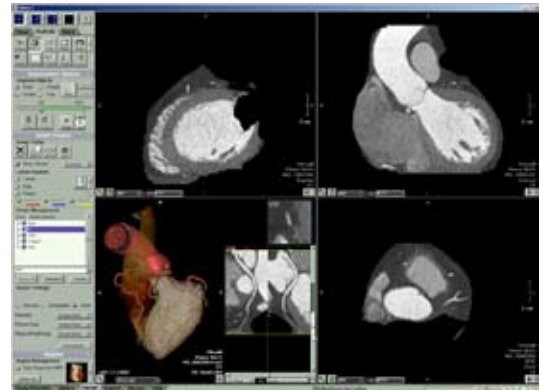


Figure 8: Evaluation of LCX

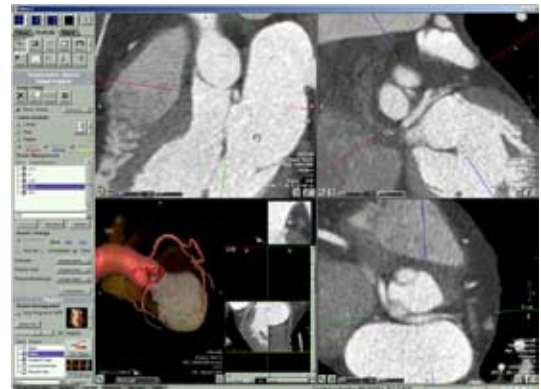


Figure 9: Evaluation of RCA

