

Clinical Case Review

Coronary Anatomy Evaluation Using Vitrea® Software

Michael Steigner, MD

Attending Radiologist

Non-Invasive Cardiovascular Imaging

Brigham and Women's Hospital, Boston, MA

msteigner@partners.org

INTRODUCTION

The patient is a 42-year-old man.

Dr. Michael Steigner imaged and evaluated the patient.

METHOD

Brigham and Women's Hospital initially imaged the patient in October 2008 using CT.

FINDINGS

The volumes into the Vitrea® system using the Cardiac Arteries CT protocol. The Short Axis view was used to begin the case by assessing the quality of the study in regard to motion, overall image noise and contrast opacification.

The quality assessment was centered around the right coronary artery (RCA), reasoning that if the RCA was relatively motion-free then the rest of the vessels would likely be as well. Some motion artifact was noted. However, there was a good short axis view of the lumen (see Figure 1). This was a diagnostic quality study and ruled that going back to capture any more post-process phases would not change the conclusion.

Some experienced radiologists choose to read an entire study in the axial mode when the study quality is good. However, accepted practice at the Brigham and Women's Hospital is to use the axial image to gain a brief overview and then walk through each vessel using oblique MPR reconstruction. First a cardiac overview was observed and all vessels were deemed evaluable before proceeding with vascular observation. If any sections had too much motion artifact to evaluate, a new diagnostic phase for that segment would have been generated on the workstation.

During this overall evaluation, vessel orientation was assessed any stenoses or areas of bridges were reviewed. Due to administration of nitroglycerin prior to the study, the patient's coronary arteries were nicely sized. (Once a vessel gets below 1.5–2 mm in diameter, it becomes too small to reliably interpret or grade stenosis.) The patient was right dominant with a large PDA and a tortuous posterior left ventricular (PLV) branch that gave off multiple branches to the left ventricle (LV) (see Figure 2). The left main (LM) and left anterior descending (LAD) arteries were identified, as well as two septal branches and three diagonal branches (D_1 – D_3) coming off of the LAD.

Figure 1: Assessment of RCA for Motion and Anomalies

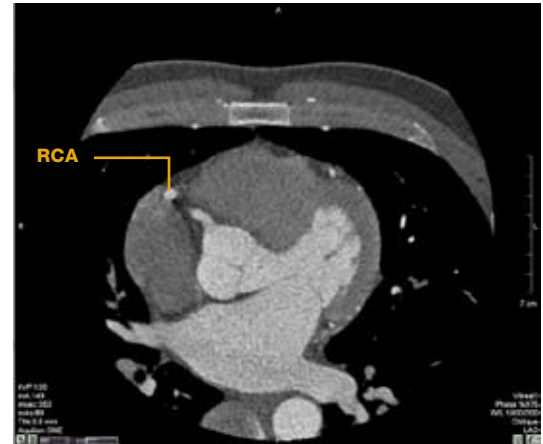


Figure 2: Cardiac Overview in Axial Mode

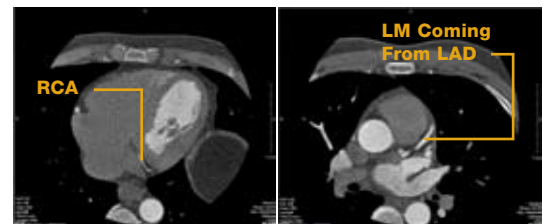
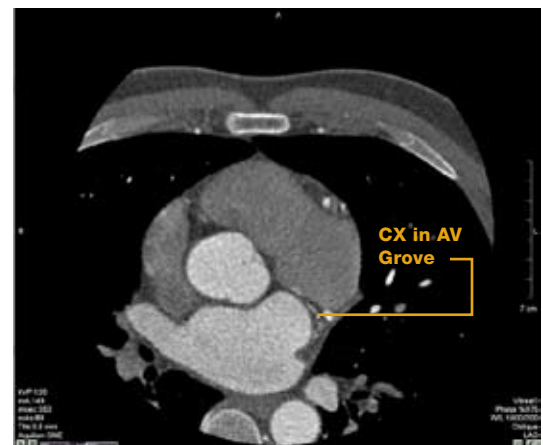


Figure 3: Visualization of Native CX in AV Groove



Clinical Case Review

Coronary Anatomy Evaluation Using Vitrea Software

An overview of the circumflex (CX) anatomy, identifying the proximal CX and a large obtuse marginal (OM) branch was obtained. The native CX stayed in the arteriovenous (AV) coronary and continued to hug the AV groove near a small branch to follow it around the heart.

Oblique MPR mode was used to conduct vessel evaluation. The goal was to walk down each vessel in Short Axis view. To do so, the LM (see Figure 4) was first located and realigned down the long axis of the remaining segment in the orthogonal views, as needed.

The re-centering process was repeated for the proximal LAD, using the Ruler tool to determine cessation of evaluable vessel diameter (see Figure 5).

Next, the extra-coronary anatomy was reviewed for anomalies and gross defects. There was good contrast enhancement in the left side. The left atrial appendage (LAA) was evaluated for clots, LA enlargement and the presence of small patent foraminal valleys. A small potential jet (see Figure 6) was visualized. Evaluation of the right ventricle was limited to size since the images did not have right heart filling. (The Brigham and Women's Hospital uses a saline bolus chaser and does not leave any contrast in the right heart.)

The sinus of Valsalva and the aorta (see Figure 7) were evaluated for root size, dissection and aneurysms. The aorta looked pristine in this patient and did not indicate the presence of hematoma or penetrating atherosclerotic ulcers.

Figure 4: Short Axis View of LM in Oblique MPR Mode

Figure 5: Determination of Evaluable Vessel Diameter

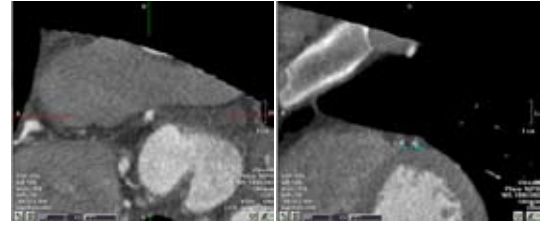


Figure 6: Identification of Potential Foramen Ovale Jet

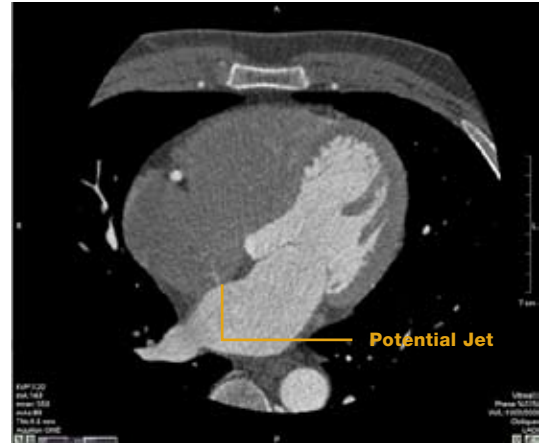
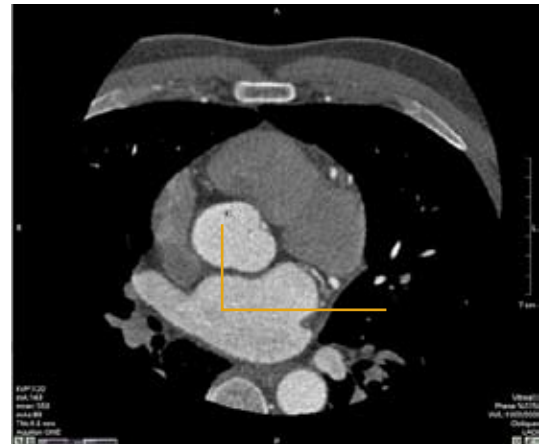


Figure 7: Visualization of Aorta



Clinical Case Review

Coronary Anatomy Evaluation Using Vitrea Software

The myocardium was evaluated (for perfusion defects, pericardial structures and fluid) and pericardium (for calcifications and fluid) and appreciated no abnormal findings (see Figure 8).

In images where there is good right heart opacification, it is important to evaluate the pulmonary arteries for clots and emboli (PEs). Full field of view is preferred for reconstructions in 5 mm slice thickness with 5 mm intervals to determine the presence of lung nodules or masses and to evaluate the structure of the chest wall and the upper abdominal organs. Lung and chest wall findings are evaluated by reformatting the image using the Lung Windows.

Following the extra-coronary evaluation, the Vessel Probe Tool was used to manually probe each vessel, including the LAD, OM, D₁ and D₂. The Vitrea system automatically identified the centerline for the LAD, RCA and LCX, enabling scrolling through the entire vessel and editing as needed (see Figure 9).

Even though it was a good quality study with good segmentation, the curved planar reformats are always vulnerable to an imperfect centerline, and lesions seen in CPR must always be correlated with the source images.

As a final step, batch images were generated to send to PACS using 3D volume rendering for localization. The images were rotated around the centerline to select the best orientation while taking snapshots of each branch. A batch rotating movie of heart (see Figure 10) was generated and as well as a report of the findings.

CONCLUSION

A batch of 3D images were generated for the referring physician(s) to quickly load on PACS in order to view the patency of vessels and the presence of stenoses. If fellows post-process the cases initially, they could quickly look at these images to evaluate whether they are good enough to archive in PACS.

Figure 8: Visualization of Myocardium and Pericardium

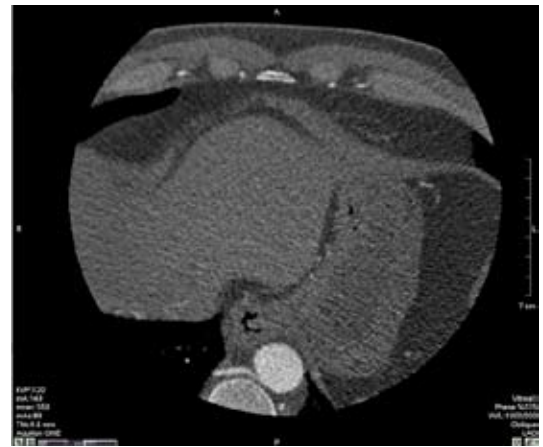

Figure 9: Vessel Probe of LAD

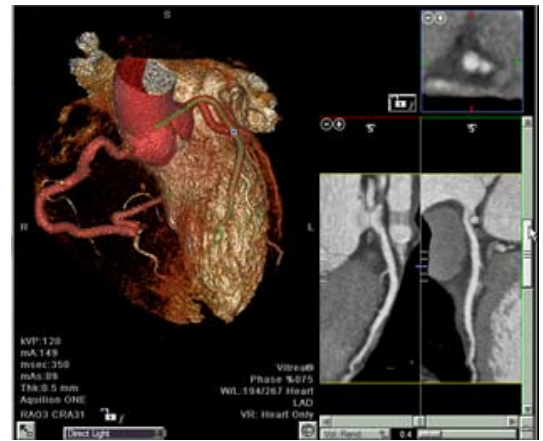


Figure 10: Creation of Batch Rotating Movie

