

Clinical Case Review

Evaluation for Redo CABG Using Vitrea® Software

Michael Steigner, MD

Attending Radiologist

Non-Invasive Cardiovascular Imaging

Brigham and Women's Hospital, Boston, MA

msteigner@partners.org

INTRODUCTION

The 83-year-old male patient required a redo CABG. He had a saphenous vein bypass graft with stents lining the entire graft from the aorta to the obtuse marginal. During the last catheterization, he also had a dissection from the RCA back into the aorta.

Dr. Michael Steigner imaged and evaluated the patient in this case as a service provided to his vascular surgeons. The intent of this evaluation was to demonstrate the relationship of the sternal wires to the bypass graft. By providing 2D measurements and a 3D image, wire damage could be avoided when the chest was re-opened.

METHOD

Shapiro Cardiovascular Center initially imaged the patient in October 2008 using CT.

FINDINGS

Using the Cardiac Arteries protocol, the Vitrea® software generated a 3D color image. The case began by reviewing the occlusion of the saphenous vein graft and the false lumen of the dissection, which extended superiorly and stopped before the arch vessels (see *Figure 1*). This patient was acquired as a thoracic aorta study rather than a coronary artery study, which explained the wide coronary artery amalgamation in the images. However, this protocol is preferred for demonstrating the relationship between the left internal mammary artery (LIMA) and the right internal mammary artery (RIMA), as well as any relevant saphenous venous grafts to the sternal wires.

The Anatomy Editor was first used to probe and segment the LIMA and RIMA (see *Figure 2*).

Figure 1: Review of the Occlusion and Dissection

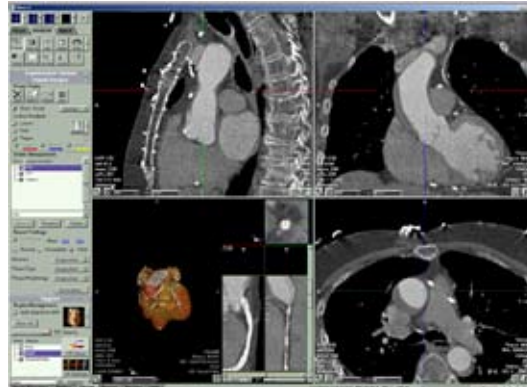
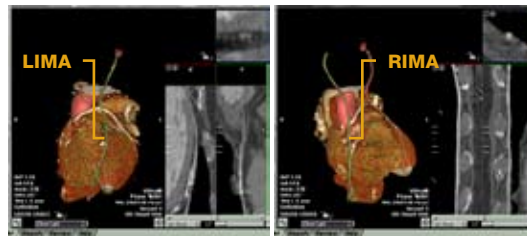
Figure 2: Manual Probe of Two Vessels



Clinical Case Review

Evaluation for Redo CABG Using Vitrea Software


The sternum and the sternal wires were then segmented out using the Curved Planar Reformat inset view (see *Figure 3*) and added the aorta back to the Base layer using Vessel Probe. At this point, 3D visualization of the heart was complete, including the sternum, wires, RIMA and LIMA. The heart, sternum and base appeared as semi-transparent objects.

After turning off the Base, Sternum and Heart layers, the Ruler tool was used to perform 3D distance measurements between the sternal wires and the RIMA vessel that maintained the relationship in the 3D space (see *Figure 4*).

Figure 3: Segmentation of the Sternum and Sternal Wires

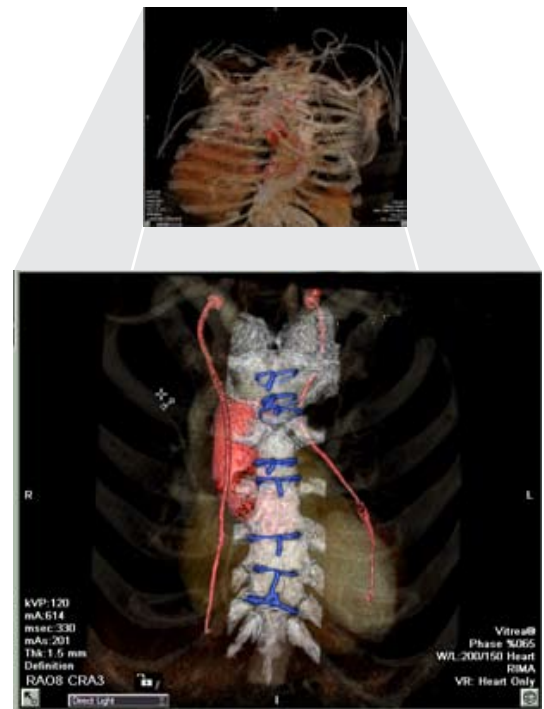

Figure 4: Measurement Between Sternal Wires and RIMA Vessel



Clinical Case Review

Evaluation for Redo CABG Using Vitrea Software

CONCLUSION

2D measurements and 3D visualization of a saphenous vein bypass graft with stents was provided in less than 10 minutes. In doing so, the relationship between the sternal wires and the bypass graft were demonstrated so that vascular surgeons could avoid damaging the grafts when they re-entered the patient's chest for a CABG redo.

Figure 7: Visualization of All Relationships

